

02/07/08 THU 15:01 FAX 305 547 0259

002

IN THE CIRCUIT COURT OF THE ELEVENTH JUDICIAL CIRCUIT
IN AND FOR MIAMI-DADE COUNTY, FLORIDA

STATE OF FLORIDA,

Plaintiff,

CASE NO: F07-42284

JUDGE: Murphy

vs.

Eric Rivera,
Jason Scott Mitchell,
Charles Wardlow
and Venjah Hurte
Defendant(s).

AMENDED DISCOVERY EXHIBIT

COMES NOW KATHERINE FERNANDEZ RUNDLE, State Attorney of the Eleventh Judicial Circuit of Florida, by and through the undersigned Assistant State Attorney, and files this Amended Discovery Exhibit under Florida Rule of Criminal Procedure 3.220, as follows:

1. Medical Examiner's Autopsy Protocol
2. Medical Examiner's Toxicology Report
3. Medical Examiner's Autopsy Sketch
4. Medical Examiner's Autopsy Dictation
5. Medical Examiner's Investigation Report
6. Medical Examiner's Preliminary Police Death Investigative Report

Respectfully submitted

KATHERINE FERNANDEZ RUNDLE
State Attorney

By: 
Rena Rubin
Assistant State Attorney
Florida Bar #715123
1350 N.W. 12th Avenue
Miami, FL 33138-2111
(305) 547-0100

CERTIFICATE OF SERVICE

I HEREBY CERTIFY that a true and exact copy of the above was furnished to Wilbur C. Smith, III, Esquire, PO Box Drawer 8, Suite 100, Ft. Myers, Florida 33902, Landon B. Miller, Esquire, Lake Avalon Center, 4280 E. Tamiami Trail, Suite 204, Naples, Florida 34112, David Brenner, Esquire, 2133 Main Street, Ft. Myers, Florida 33901, Michael Homung, Esquire, 15811 New Hampshire Court, Ft. Myers, Florida 33908, on this 4th day of February, 2008.


Assistant State Attorney

02/07/08 THU 15:01 FAX 305 547 0259

003



MIAMI-DADE COUNTY
MEDICAL EXAMINER DEPARTMENT
Number One on Bob Hope Road
Miami, FL 33136
Phone (305) 545-2400 Fax (305) 545-2439



AUTOPSY PROTOCOL

TAYLOR, Sean
November 27, 2007...9 A.M.

Case No. 2007-02963

CAUSE OF DEATH:

Gunshot Wound of Lower Extremities


Satish Chundru, D.O.
Associate Medical Examiner

Date: 12/21/07

SCR/AAA8/18

02/07/08 THU 15:01 FAX 305 547 0250

004



MIAMI-DADE COUNTY
MEDICAL EXAMINER DEPARTMENT
TOXICOLOGY DEPARTMENT
Number One on Bob Hope Road
Miami, FL 33136
Phone (305) 545-2400 Fax (305) 545-2418



TOXICOLOGY REPORT

ME CASE #. **2007-02913**

DECEDENT'S NAME: **TAYLOR, SEAN MICHAEL MAURICE**

<u>SUBSTANCE</u>	<u>SPECIMEN</u>	<u>RESULTS</u>	<u>NOTES</u>
VOLATILES	BLOOD ANTEMORTEM	UNDETECTED	Purple top tube dated 11/26/07; 02:43.
BARBITURATES	BLOOD ANTEMORTEM	UNDETECTED	Purple top tube dated 11/26/07; 02:43.
BENZODIAZEPINES	BLOOD ANTEMORTEM	UNDETECTED	Purple top tube dated 11/26/07; 02:43.
BENZOYLECGONINE	BLOOD ANTEMORTEM	UNDETECTED	Purple top tube dated 11/26/07; 02:43.
OPIATES	BLOOD ANTEMORTEM	UNDETECTED	Purple top tube dated 11/26/07; 02:43.
BASIC DRUGS	BLOOD ANTEMORTEM	UNDETECTED	Purple top tube dated 11/26/07; 02:43.

[Signature]
CHUNDRU, SATISH D.O.

12/21/07

Date

[Handwritten initials]

12/19/2007 2:51:24 PM

02/07/08 THU 15:01 FAX 305 547 0259

005

DADE COUNTY MEDICAL EXAMINER DEPARTMENT, MIAMI, FLORIDA**DR. Sean...November 27, 2007...9:00 A.M. ...Case No. 2007-02963****EXAMINATION:**

body is that of a 6 foot, 3 inch, 339 pound, black male who appears the reported age of 24. The body has severe anasarca. The scalp hair is black and has braids. Facial hair consists of a mustache and mustache. The irides are dark brown and have no arcus senilis. The sclerae are white to yellow. The conjunctivae are edematous and are free of petechiae. The ears are normally formed and the external auditory canals are patent. The nares are patent and the nasal septum is not perforated. The oral mucosa is tan-purple, moist and intact. The teeth are natural and in good repair. The head is uninjured. The neck is symmetric and the trachea is midline. The neck is free of injury.

The chest and abdomen are free of injury. The abdomen is flat. The upper and lower extremities are symmetric. The extremities are edematous. The shins have patchy scars. The lateral aspect of the right shoulder and right upper arm has the following tattoos: "Hold My Own," an unidentifiable tattoo below the phrase "Hold My Own" and below the unidentifiable tattoo is the word "Standing." The anterior right forearm has a designer tattoo of a dollar sign. The posterior right upper arm has a tattoo of the letters "Aulga" written vertically. The lateral left shoulder/left upper arm has the following tattoos: "Psalm," below this word is scripture writing of Psalm 25; 3, 4, below this is a tattoo of prayer hands, and below the prayer hands is the phrase "God Forgive Me." The posterior left upper arm has a tattoo of the name "Donna" written vertically. A green tattoo of a necklace encircles the entire neck and goes down to the lower chest; attached to the necklace are two medallions with the words "Dade" and "Made." The back is symmetric and free of injury. The upper back has a tattoo of a city skyline and below the skyline is the name "Taylor." The penis is circumcised and the testicles are descended. The external genitalia are free of injuries or lesions. The anus is unremarkable. A blue tag around the right wrist has the number "87259."

EVIDENCE OF MEDICAL INTERVENTION:

An intubation tube in the oral cavity is appropriately placed. A gastric tube is in the right nostril and is appropriately placed. A triple lumen catheter is in the right subclavian area and left groin. An intravenous line is in the right antecubital fossa. A urinary catheter is in the penile urethra and is appropriately placed. An approximately 40 centimeter horizontal thoracotomy is just below the nipple. The pericardial sac has been incised. A chest tube is in the left side. A clear yellow plastic material is over the abdomen. The small and large bowels and stomach are exposed and are red to dark green; the bowels are exposed by an approximately 45 centimeter vertical midline incision of the abdomen. Drainage tubes are in the right and left abdomen. Bloody gauze is over the right groin and a drainage tube is also in the right groin. A suction drainage apparatus is on the left side of the chest. Blood soaked gauze is around the right shin. The lateral and medial aspects of the right shin have vertical incised wounds that are 21 centimeters and 26 centimeters, respectively.

EVIDENCE OF INJURY:**PENETRATING GUNSHOT WOUND OF THE LOWER EXTREMITIES:**

The right groin has an incised wound that is stitched and stapled in a Y-shaped configuration. Along the edges of the incision is an area that is abraded. This abraded area is approximately 38 inches above the bottom of the right heel. Probing the exit wound, the probe extends to this abraded area of the

02/07/08 THU 15:02 FAX 305 547 0259

006

THE MIAMI-DADE COUNTY MEDICAL EXAMINER DEPARTMENT, MIAMI, FLORIDA**TAYLOR, Sean...November 27, 2007...9:00 A.M. ...Case No. 2007-02963**

tion. Soot and stippling are not visible in the abraded area.

The projectile perforates the soft tissues and muscles of the right groin, the right femoral artery, the muscles of the right upper thigh, and exits the medial/posteromedial right upper thigh 35 inches above the bottom of the right heel. The exit wound is 1.6 x 0.9 centimeters and has no abrasions, soot or stippling. Skin tags are at the 5 o'clock and 9 o'clock positions.

The projectile continues and enters the medial left upper thigh 34 inches above the bottom of the left heel. The reentry wound is 1.3 x 1.2 centimeters and has a 0.2 centimeter in width brown-red abrasions at the 12 o'clock, 5 o'clock and 6 o'clock positions. Soot and stippling are not visible. The projectile perforates the soft tissues and muscles of the posterior mid to lower left thigh and a projectile is recovered under the skin of the posterior lower left thigh. The projectile is fairly intact and is recovered approximately 24 inches above the bottom of the left heel. The projectile is placed in an appropriately labeled evidence envelope.

Associated with the wound pathway is hemorrhage in the musculature of both thighs. The right femoral artery has a graft that is intact and patent. The right femoral vein is not disrupted.

The wound pathway, with the body in the normal anatomic position, is right to left, front to back and downward.

OTHER INJURIES:

A 2 x 1 centimeter superficial ovoid abrasion is on the anteromedial right mid bicep.

INTERNAL EXAMINATION:

The chest and abdominal wall musculature has focal areas of hemorrhage associated with the medical interventions. The organs are in their normal anatomic positions. The ribs and clavicles are intact. The left pleural cavity has approximately 2250 cubic centimeters of blood, blood clot, and fibrinous material. The right chest cavity has approximately 100 cubic centimeters of serous fluid. The right pleural cavity has no adhesions. The left pleural cavity has loose fibrinous adhesions. The abdominal cavity has loose fibrinous adhesions between the loops of bowel. The strap muscles of the neck have no hemorrhage or injury.

The heart is 580 grams and has an intact epicardium that has patchy areas of fibrinous adhesions. The apex is sharp. The coronary ostia are patent and normally situated. The coronary circulation is right dominant and has minimal atherosclerotic disease. The myocardium is tan-brown, firm, and has no necrosis or scars. The papillary muscles are tan-brown and firm. The chordae tendineae are thin, delicate and separate. All four cardiac valves are normally formed and are free of vegetations, injuries, or ballooning changes. The fossa ovalis is fused. The aorta is patent and has minimal atherosclerotic disease consisting of fatty streaks and uncomplicated plaques.

The right and left lungs are 1100 grams and 860 grams, respectively. The pleural surfaces are light purple and have very minimal anthracotic pigmentation. The parenchyma is deep red-brown, rubbery and has no neoplasm, nodules or necrosis. Clear fluid is expressed from the lung parenchyma.

02/07/08 THU 15:02 FAX 305 547 0250

007

THE MIAMI-DADE COUNTY MEDICAL EXAMINER DEPARTMENT, MIAMI, FLORIDA**TAYLOR, Stuart...November 27, 2007...9:00 A.M. ...Case No. 2007-02963**

The tracheobronchial tree and pulmonary vascular tree arborize in a normal pattern and are free of mucous plugs and thromboemboli, respectively. The larynx and trachea are lined by pink-tan mucosa without neoplasm or deposits. The hyoid bone and thyroid cartilage are intact.

The tongue is unremarkable. The esophageal mucosa is light tan and has no neoplasm. The stomach contains approximately 500 cubic centimeters of dark brown fluid and partially digested rice and beans. The stomach serosa is smooth and the mucosa has no neoplasm or ulcers. The small and large intestines have serosas as previously described and have no palpable neoplasm or diverticula. The appendix is normal. The rectum is filled with brown liquid stool.

The liver is 2770 grams and has a smooth, glistening, intact capsule. The parenchyma is mildly firm, and has no neoplasm, nodules or necrosis. The lobules have an alternating red and tan pattern. The gallbladder has a smooth serosa, a normal, velvety, green mucosa and contains approximately 15 cubic centimeters of viscous, amber bile.

The pancreas has a uniform, tan-brown, lobular parenchyma.

The adrenal glands have yellow-brown cortices and gray medullae. The thyroid gland is not enlarged and has a homogenous, dark purple parenchyma without neoplasm or nodules.

The spleen is 250 grams and its parenchyma is firm and has no infarcts. The white pulp is unremarkable. A 2.5 x 2.2 x 1.5 centimeter well circumscribed tan-brown smooth lesion is in the parenchyma just below the capsule.

The right and left kidneys are 260 grams and 270 grams, respectively. The cortical surfaces are smooth, red-brown and glistening. The parenchyma is red-brown, has distinct corticomedullary junctions and no neoplasms, nodules or necrosis. The ureters are normal in course and caliber to the bladder. The bladder is lined by white-tan, smooth mucosa and contains no urine.

The prostate gland is not enlarged and has a homogenous, symmetric, tan-gray parenchyma without neoplasm or nodules. The testicles are covered by smooth, white tunica and have homogenous, tan parenchyma.

The scalp is uninjured. The calvarium is intact. The brain is 1470 grams and is not edematous. The gyri are of normal caliber and the sulci are unremarkable. No hemorrhage is in the epidural, subdural and subarachnoid spaces. The cerebral hemispheres are symmetric. The gray matter is unremarkable, free of contusions, and is clearly delineated from the white matter. The ventricles are not dilated and have a normal choroid plexus. The basal ganglia, thalami, hippocampi, amygdalae, substantia nigra, and mammillary bodies are symmetric and normally formed. The cerebellum and brainstem have no external or internal abnormalities. The vessels of the circle of Willis are patent and are free of atherosclerosis or abnormality. The anterior, middle and posterior cranial fossae are free of fractures. The pituitary gland appears normal within the sella turcica. The vertebral column and spinal cord are uninjured; the spinal cord has no lesions.

02/07/08 THU 15:03 FAX 305 547 0259

008

THE MIAMI-DADE COUNTY MEDICAL EXAMINER DEPARTMENT, MIAMI, FLORIDA

TAYLOR, Sean...November 27, 2007...9:00 A.M. ...Case No. 2007-02963

OPSY FINDINGS:

1. Penetrating gunshot wound of lower extremities; projectile recovered.
2. Abrasion of the right mid bicep.
3. Right femoral artery graft intact and patent.
4. Splenic lesion.


Satish Chundru, D.O.
Associate Medical Examiner

SCR/AAA8/18

02/07/08 THU 15:03 FAX 305 547 0259

009



MIAMI-DADE COUNTY MEDICAL EXAMINER DEPARTMENT

Number One on Bob Hope Road
Miami, FL 33136
Phone (305) 545-2400 Fax (305) 545-2418



INVESTIGATION REPORT

M.E. Case #: 2007-02963

DATE: 11/27/2007

Type: ME

TAYLOR, Sean Michael Maurice

24 Years Black Male

D.O.B. 4/1/1983

18050 Old Cutler RD Palmetto Bay, FL

PLACE OF DEATH: Jackson Memorial Hospital

TIME OF DEATH: 27-Nov-2007 3:35 AM

INVESTIGATING AGENCY: Miami-Dade Police Department PD071126-636683 Det. Segovia

INCIDENT LOCATION: 18050 Old Cutler RD, Palmetto Bay, FL 33167

INCIDENT DATE / TIME: 11/26/2007 1:48:00 AM SCENE DR.:

TERMINAL EVENT: According to the initial police investigation, on November 26, 2007, abt. 1:40a.m., the deceased, his girlfriend and baby were in the bedroom of his residence when he was awakened by noises from within the residence. Unknown subject(s) had broken into the residence, kicked in the bedroom door and shot him as he attempt to defend himself. After the shooting the subjects fled and his girlfriend summoned Police and Fire. Upon the arrival of fire rescue, he was in a prone position, and with agonal respirations (4-6). He was turned over and found to have a carotid pulse. His pupils were unreactive and dilated. A gunshot wound was noted to the right femoral artery without exit wound. Another wound was noted to the right bicep which appears to be a graze from a bullet. A blood pressure was unobtainable. Emergency medical treatment was administered and he was transported to Jackson Memorial Hospital via air-rescue.

Upon arrival at the emergency room, he was unresponsive with a gcs of 3. He was transported to the operating room with pre-op diagnosis of cardiac arrest, a/p gunshot wound to the right thigh. Post Operative diagnosis: Status Post cardiac arrest secondary to hemorrhagic shock from gunshot wound to right side femoral artery. Procedure: Emergency thoracotomy, left tube thoracotomy, right groin exploration repair of right side femoral artery transection with 8mm graft. His abdomen was open and he was found to have ischemic bowel. Advance life support was administered, however, at 2:41am he went into asystole, then bradycardia. Advance life support was continued, however, without success and at 3:36am, he was pronounced dead.

MEDICAL HISTORY: According to his father, he had not been under the care of a doctor for any medical problems.

MEDICATIONS: None

SOCIAL HISTORY: According to his father, he was born in Hartford Connecticut and has resided in Miami-Dade for 23 years. He was not married, but was the father of one child. He was not a user of recreational drugs nor did he drink alcoholic beverages or smoke cigarettes. He was a professional football player with the National Football League and employed as a Safety with the Washington Redskins. He injured his knee early in the 2007-2008 season and was at home to see an

CAUSE OF DEATH: Gunshot Wound of Lower Extremities

DUE TO:

DUE TO:

DUE TO:

CONTRIBUTORY CAUSE:

MANNER: Homicide Autopsy


11/27/2007 9:00 AM **DOCTOR:** Chundru, Satish D.O.

MORTUARY: POITIER FUNERAL HOMES

INVESTIGATOR: Boyd, Sandra

THIS REPORT MAY CONTAIN NON-VERIFIED INFORMATION
AND IS SUBJECT TO CHANGE

12/13/2007 8:14:18 PM



MIAMI-DADE COUNTY MEDICAL EXAMINER DEPARTMENT

Number One on Bob Hope Road
Miami, FL 33136

Phone (305) 545-2400 Fax (305) 545-2418



INVESTIGATION REPORT

M.E. Case #: 2007-02963

DATE: 11/27/2007

Type: ME

TAYLOR, Sean Michael Maurice

24 Years

Black

Male

D.O.B. 4/1/1983

18050 Old Cutler RD Palmetto Bay, FL

PLACE OF DEATH: Jackson Memorial Hospital

TIME OF DEATH: 27-Nov-2007 3:35 AM

INVESTIGATING AGENCY: Miami-Dade Police Department PD071120-635583 Det. Segovia

INCIDENT LOCATION: 8050 Old Cutler RD , Palmetto Bay, FL 33157

INCIDENT DATE / TIME: 11/26/2007 1:46:00 AM

SCENE DR.:

SOCIAL HISTORY: According to his father, he was born in Hartford, Connecticut and had resided in Miami-Dade for 23 years. He was not married, but was the father of one child. He was not a user of recreational drugs nor did he drink alcoholic beverages or smoke cigarettes. He was a professional football player with the National Football League and employed as a Safety with the Washington Redskins. He injured his knee early in the 2007-2008 season and was at home to see an orthopedic surgeon for a second opinion on his knee.

IDENTIFICATION:

METHOD: Visual

BY: Pedro Taylor

RELATIONSHIP: Father

CAUSE OF DEATH: Gunshot Wound of Lower Extremities

DUE TO:

DUE TO:

DUE TO:

CONTRIBUTORY CAUSE:

MANNER: Homicide

Autopsy

11/27/2007 9:00 AM DOCTOR: Chundru, Satish D.O.

MORTUARY: POITIER FUNERAL HOMES

INVESTIGATOR: Boyd, Sandra

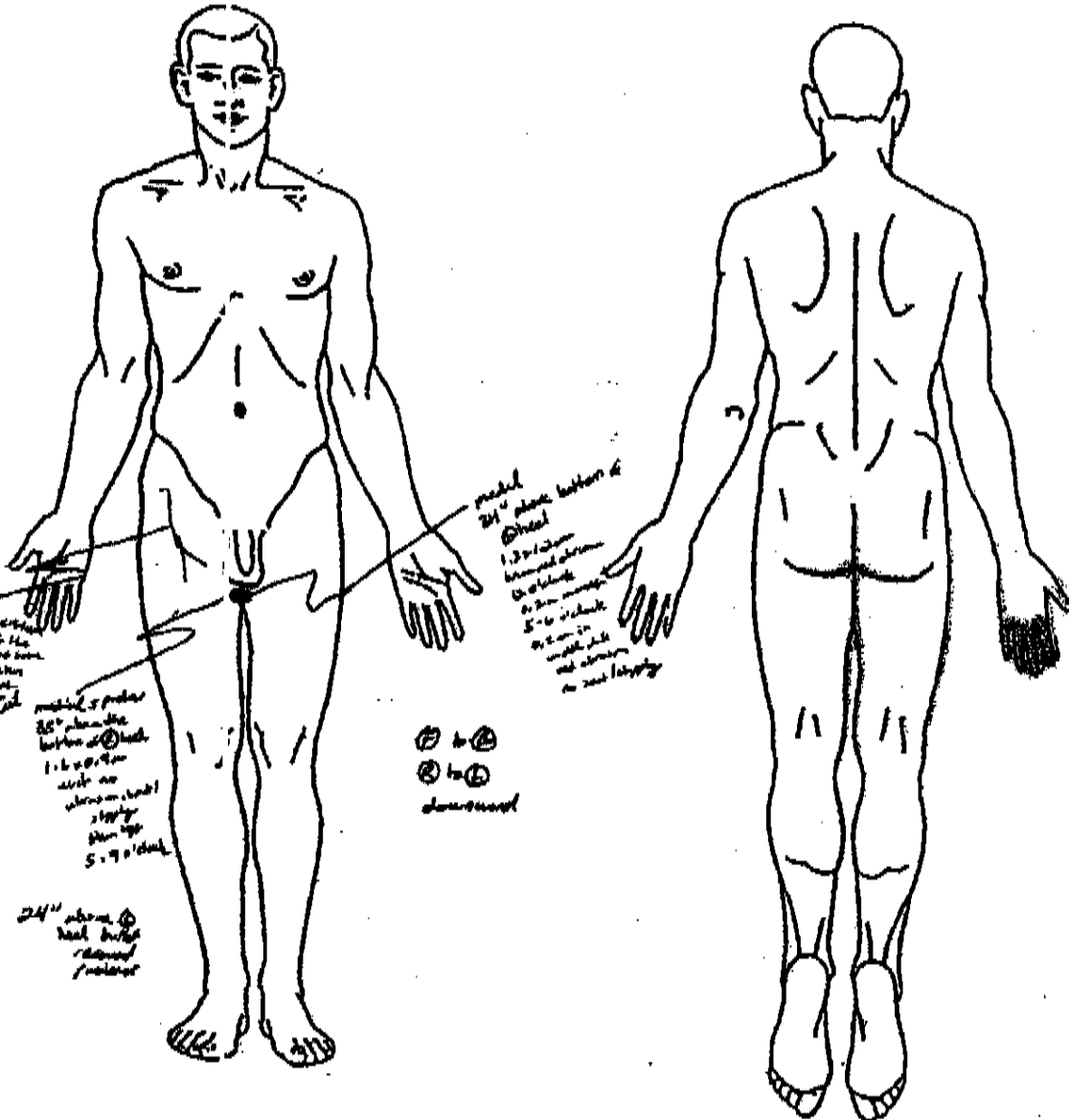
THIS REPORT MAY CONTAIN NON-VERIFIED INFORMATION
AND IS SUBJECT TO CHANGE

02/07/08 THU 15:04 FAX 305 547 0250

011

CASE NO. 07-2963 NAME _____

AGE _____ RACE _____ SEX _____ HEIGHT _____ WEIGHT _____



significant markings
and scars at the
wrist and forearm
approximately 3-4"
3-4" above
wrist

midline of pubis
36" above the
bottom of chest
1.6 x 0.4 cm
with no
ulceration, scab
or scaly
skin
5.9" dia.

24" above
heel bone
round
fascioid

midline
24" above bottom of
chest
1.3 x 0.4 cm
ulcerated scab
to the middle
of the scab
5-6" in
width, 1-2"
in depth
no nail loss

① to ②
③ to ④
downward

FORM A

02/07/08 THU 15:05 FAX 305 547 0259

013



DADE COUNTY MEDICAL EXAMINER DEPARTMENT
NUMBER ONE ON BOB HOPE ROAD, MIAMI FL 33136-1133
TELEPHONE (305) 545-2400
FAX (305) 545-2418

AUTOPSY DICTATION

DR. SC

DATE 11/27/07

07-2963
ME CASE #

Sean Taylor
NAME

Homicide
MANNER

9:00 AM
TIME

HT 580
RL 1100
LL 860
L 2710

S 250
RK 260
LK 270
B 1470

AGE 24
RACE B
SEX M
HT 6'3"
WT 139 lbs

TOX SCENE or N
Y or N

RESPIRATORY SYSTEM



(D) (check) 2250

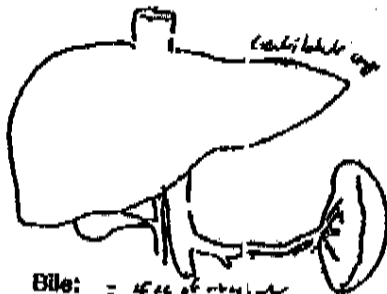


very normal
no evidence
of
collapse
or
atelectasis

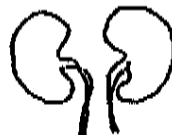R L



Dominant: R / L:
Valve circumference:
TV: MV: PV: AV:



2.5 x 2.2 x 1.8 cm
circumferential
hemorrhage
length 1.5 cm



UB



Bile: = 15 cc of bile
Stomach content: = 500 cc of white foam fluid
Urine volume: 0
Appendix: yes

02/07/08 THU 15:06 FAX 305 547 0259

014

PRELIMINARY

Police Agency M.D. P.D.
 Police Case Number P007120
635583
 Lead Detective J. SEGOLIA

Name of Deceased TAYLOR, SEAN MAURICE
 Age 33 Race W Sex M DOB 04-01-1963 Social Security
 First Last Middle

Address 18050 OLD CUTOFF RD Home Phone
ELABORN CITY POLICE DEPT
 Next of Kin Notified: Yes No
 Name: PELLO TAYLOR
 Relationship: FATHER
 Address: ELABORN CITY POLICE DEPT
 Telephone: 305-247-8223

Place of Death (Hospital, Home Address, Etc.): S.I.G.H. AVENUE THURMOR S.C.U.
 Place of Injury (Address, Location): 18050 OLD CUTOFF RD
 Injury Occurred: 4-26-07 1:42 PM
 TIME OF DEATH:
 Occurred: M D Y Time M
 Round: M D Y Time M
 Pronounced: 11-27-07 3:25 AM M D Y Time M
 Identified by: PELLO TAYLOR
 Address: ELABORN RD
 Phone: 305-247-8223

Name and Telephone of Doctors and/or Hospitals That Attended Deceased During Life: S.I.G.H.

Physical Examination of the Body (Position/Location of Body): SUPINE, HOSPITAL BED, S.C.U.

Lividity: No Yes
 Trauma: No Yes
 Describe Trauma: G.S.H. A. GROUND SCEN
PELLO TAYLOR
 Weapons Used (Possible Type) HANDGUN REV. 380
 to M.E.: No Yes
 Unknown No Yes
4-27-07 D Y 4:54 PM Time

Values: Yes No
 Impounded By:

Disposition of Clothing: Discard Not Needed Save-Hold/Dry as Evidence
 Special Instructions: Rape Kit Do Not Wash Do Not Finger/Palm Print
 Do Not Undress Take Body Temp

While Copy to Medical Examiner Department/Refer Copy to Police Department

02/07/08 THU 15:00 FAX 305 547 0259

016

MIAMI-DADE COUNTY
PRELIMINARY POLICE DEATH INVESTIGATION REPORT
 FOR THE MEDICAL EXAMINER
 Continuation Sheet

Police Case No. 97-10000-5-2

Name of Deceased [REDACTED]

Yes No

Name _____ M

Body Removal Requested _____ 3:35 PM

Body Removal Transport Arrived _____ 4:00 PM

Telephone Number 305-471-2400

Investigator to be present at Autopsy? No Yes

PLEASE NOTE WHERE APPLICABLE: Use second sheet if needed-Scene Information to Follow: What happened just prior to death? Terminal Event-Medical/Social Information-Medications.

ON Monday, 11-26-07 AT APPROX 1:40 AM THE VICTIM, MRS. GUILFRIEDA ANN BERRY WERE IN THE BEDROOM AT HIS RESIDENCE. THE VICTIM WAS AWAKENED BY SOME FALLS WITHIN THE BEDROOM. UNKNOWN SUBJECT(S) HAD BROKEN INTO THE VICTIM'S RESIDENCE. THE SUBJECT(S) KICKED IN THE BEDROOM DOOR AND SHOT THE VICTIM WHO RECEIVED TO HERSELF. THE VICTIM WAS SHOT IN THE RIGHT UPPER LEG AND THE PROXIMATE STAIRS HIS FEMORAL ARTERY. THE SUBJECT(S) FLED AND THE VICTIM CALLED FRIENDS FOR MED-RESCUE AND THE VICTIM WAS TRANSPORTED TO J.P.H. OVER THROUGH VIA AIR-RESCUE. THE VICTIM UNDERWENT SURGERY BUT EXPIRED ON 11-27-07 AT 3:35 AM, PROVIDED BY DR. DAVID KING.

White Copy to Medical Examiner Department/Yellow Copy to Police Department